Clinical Vignettes

Guido Stirnimann

COST Meeting Málaga

15.03.2019

86 y/o male patient

- Tooth extraction and paradontitis 01/2019
- 15.01.19 - 25.01.19 antibiotic treatment with **amoxicillin/ clavulanic acid and metronidazole**
- Co-medication: candesartan
- from 25.01.19 on pruritus, acholic stool, dark urine, diarhea
- 08.02.19: **bilirubin 450 µmol/L**, transaminases 2x ULN, alc. phosphatase >2x ULN

86 y/o male patient

07.02.19 abdominal CT

- Homogeneous liver parenchyma
- Vascular malformation liver segment V
- Normal gall bladder and bile ducts
- No suspicious intrabdominal mass

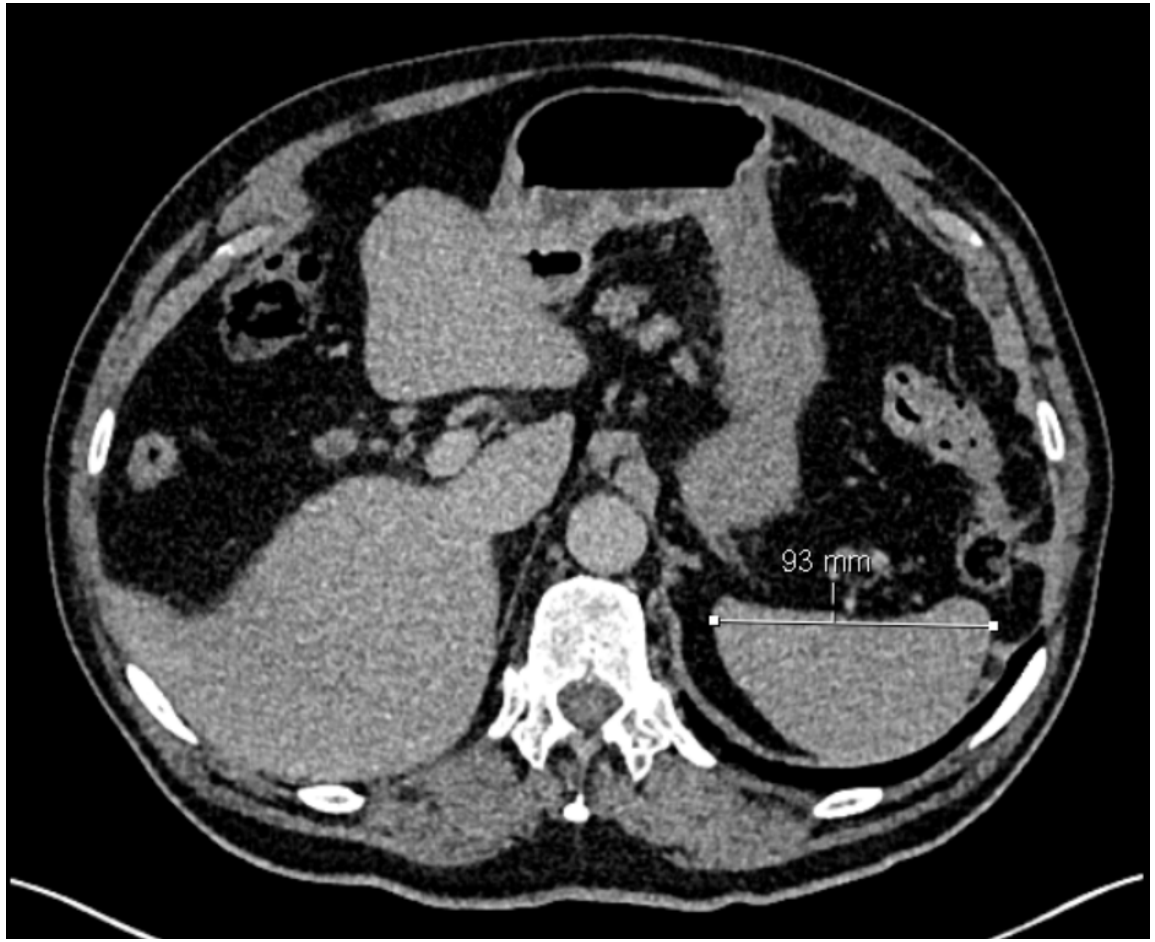

86 y/o male patient

Medication

Candesartan	stopped because of dizzyness
Cetirizin	without effect
Colestyramin (BAS)	started 05.02.2019
Naltrexin	started 15.02.2019, 25 mg per day

86 y/o male patient

Orthostatic

Haemoglobin drop
from 155 to 62 g/L

No singns for GI
bleeding

86 y/o male patient

Orthostatic

Haemoglobin drop from 155 to 62 g/L

No singns for GI bleeding

Duodenal ulceration

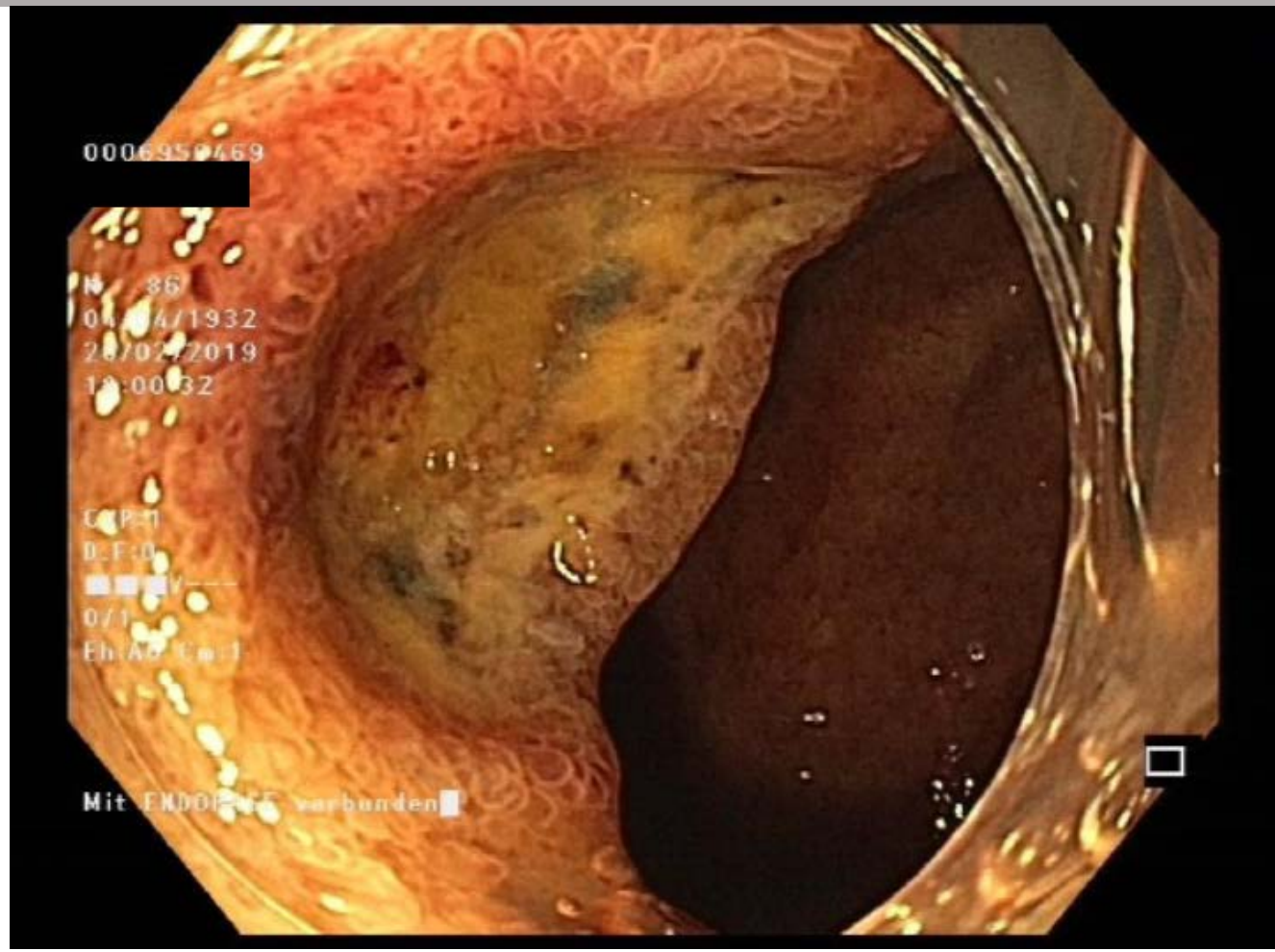

86 y/o male patient

Haemoglobin

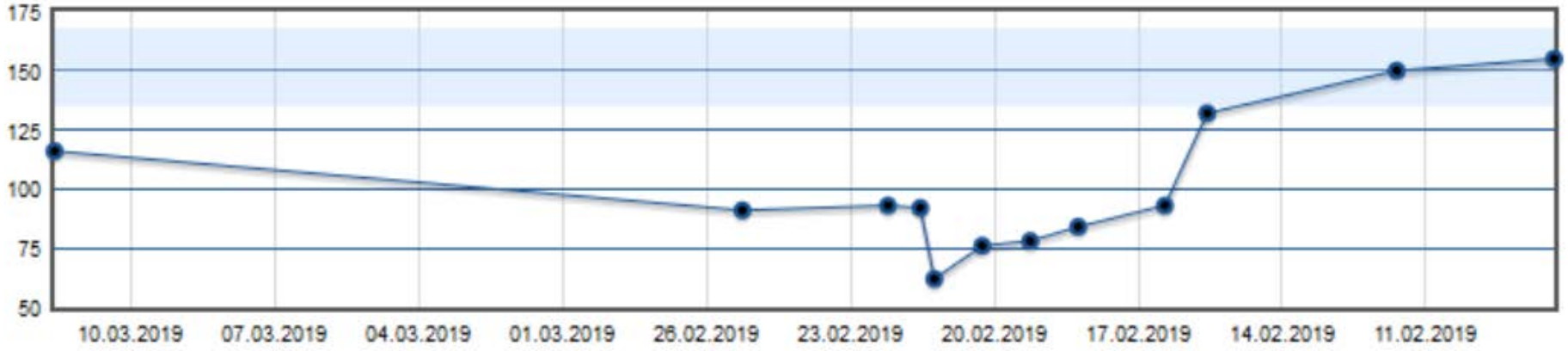

Bilirubin

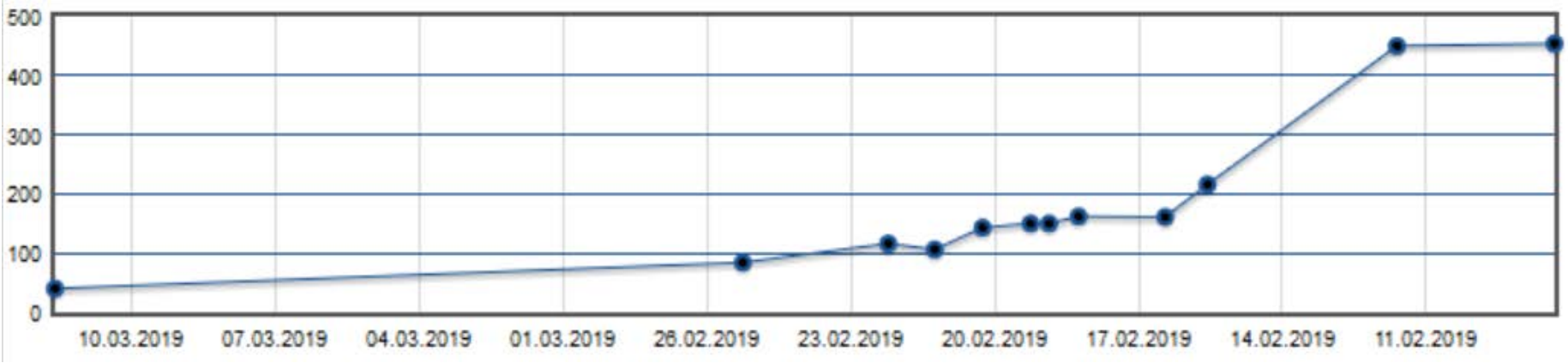

43 y/o male patient

03/2013

Acute mitral valve insufficiency because of tendinous cord rupture

Mechanical mitral valve replacement and tricuspid valve annuloplasty

Oral anticoagulation with **phenprocoumon** (vitamin K antagonist)

05/2014

Mixed hepatocellular cholestatic hepatitis

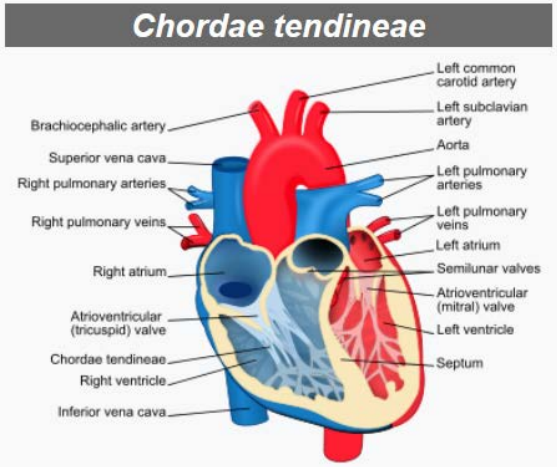

The **chordae tendineae** connect the valves to the heart muscle

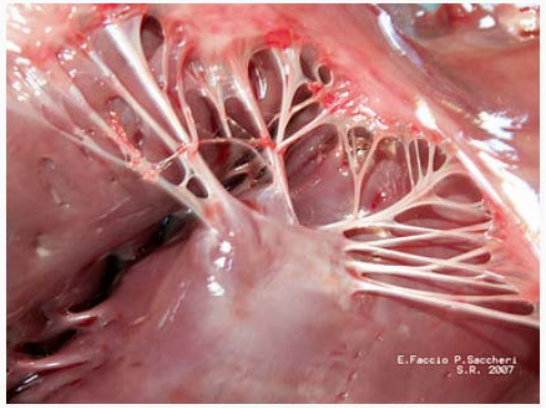

Papillary muscles and chordae tendineae

en.wikipedia.org/wiki/Chordae-tendineae

43 y/o male patient

05/2014
Mixed hepatocellular cholestatic hepatitis

Phenprocoumon stopped (started 03/2013)
Anticoagulation with **LMWH** started
Treatment with steroids due to suspicion of AIH

08/2014
Liver tests normal (after tapering of steroids)

43 y/o male patient

How to proceed?

43 y/o male patient

LMWH: current treatment

Dabigatran: unfavorable results compared to warfarin (RE-ALIGN Studie, N Engl J Med. 2013;369(13):1206.)

Rivaroxaban: no results regarding mitral valve replacement available, results from studies for aortic valve pending

Vitamin K antagonist: ?

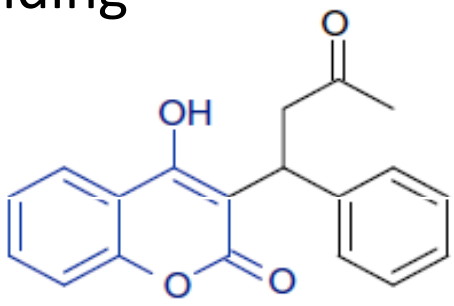

Warfarin

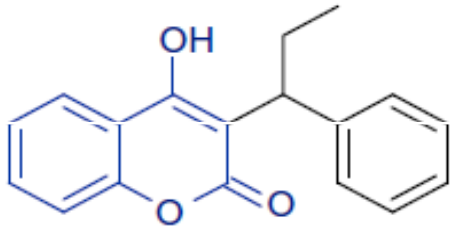

Phenprocoumon

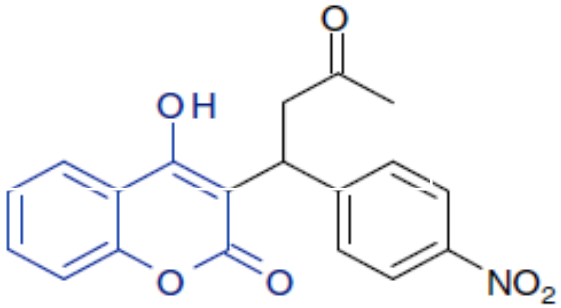

Acenocoumarol

55 y/o female patient

Adenocarcinoma of the lung with cerebral metastases

cT3 cN0 cM1c (BRA, PUL), Stadium IVB, 08/2018

Treatment

Whole brain radiation 30 Gy 09/10 2018

Start Tagrisso (Osimertinib) 10/2018

Osimertinib

Tyrosinkinase inhibitor (TKI); selective irreversible inhibitor of EGFR with sensitizing mutations (EGFRm) and the TKI-resistance mutation T790M

55 y/o female patient

	11.10.2018	25.10.2018	01.11.2018
Bilirubin (mcmol/L)	4	5	191

55 y/o female patient

01.11.2018 CT abdomen:

- Prominent central intrahepatic bile ducts
- No flow-obstructing lesion
- Pleural effusion L

55 y/o female patient

Viral:

A/B vaccinated; hepatitis C, HIV negative; CMV, EBV past infection

Autoimmune: negative

Metabolic/genetic: alpha-1-AT, coeroplasmin normal, ferritin elevated

55 y/o female patient

Bx liver 14.11.2018:

- mostly microvesicular steatosis
- bland cholestasis
- no chronic or active hepatitis
- no group necrosis
- no fibrosis

55 y/o female patient

	11.10.2018	25.10.2018	01.11.2018	13.11.2018
Bilirubin (mcmol/L)	4	5	191	380
AST			195	266
ALT			201	243
AP			723	1124
GGT			968	965
Albumin			17	21
INR			1.07	1.11

55 y/o female patient

		Anforderungsdatum	08.11.2018 09:12	06.11.2018 08:29	05.11.2018 09:19	02.11.2018 15:17	01.11.2018 14:54	25.10.2018 10:59	11.10.2018 10:15
		Info							
Name	**Einheit**	**Referenz**	**Wert**						
▼ Blut: Metabolite									
Bilirubin gesamt	µmol/L	< 17	378 +	346 +	316 +	218 +	191 +	5	4
Bilirubin direkt	µmol/L	< 5				204 +			
▼ Blut: Enzyme									
ASAT	U/L	< 35	325 +	291 +	274 +	214 +	195 +	91 +	15
ALAT	U/L	< 35	259 +	249 +	236 +	208 +	201 +	42 +	18
alk. Phosphatase	U/L	35 - 104	1023 ++	920 ++	855 +	720 +	723 +	143 +	49
G-Glutamyltransferase	U/L	< 40	1045 ++	1068 ++	1028 ++	963 +	968 +	138 +	22

55 y/o female patient

Bilirubin (total)

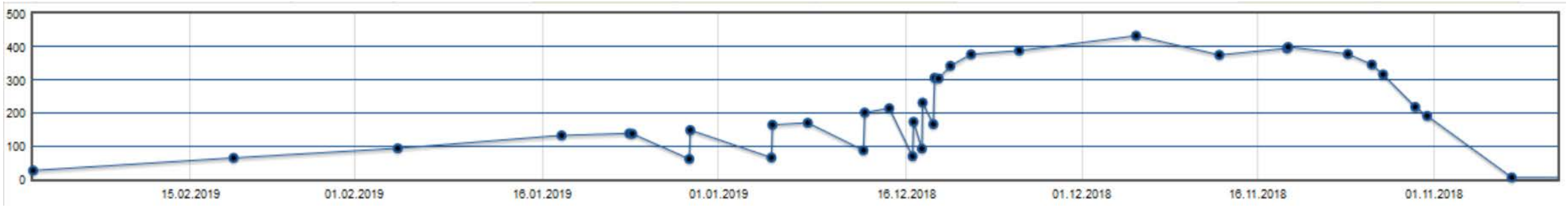

55 y/o female patient

Clinical problems

Severe pruritus

Not responding to treatment with colestyramin (BAS) and naltrexin

Plasmapheresis from 13.12.2018 to 03.01.2919

Loss of appetite and subsequently of body weight

Enteral tube feeding with consecutive increase of body weight

55 y/o female patient

Bilirubin (total)

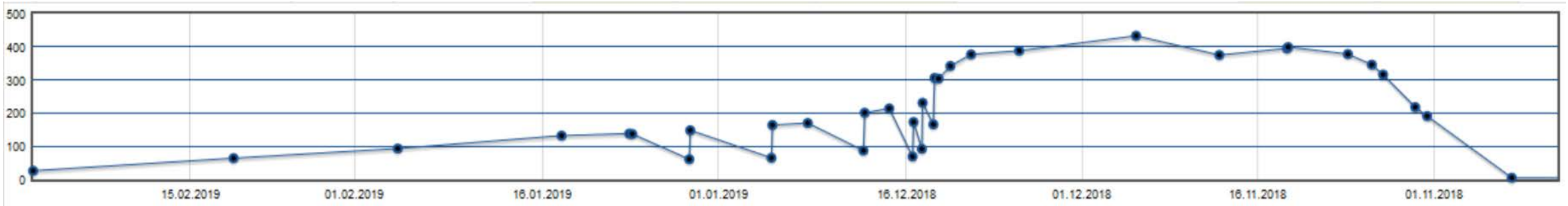

Osimertinib Hepatotoxicity

Elevations in serum aminotransferase levels are uncommon during osimertinib therapy occurring in 4% to 5% of patients and rising above 5 times the upper limit of the normal range in only 1% or less.

In preregistration trials, there was a **single incidence of clinically apparent liver injury attributed to osimertinib therapy**, but the clinical features and relatedness to therapy were not defined.

Since its approval and more widespread use, there have been **no published cases of liver injury due to osimertinib**.

60 y/o female patient

Metastatic malignant melanoma 10/2018

- Metastatic lesions in pelvis (13 cm) and pancreas
- Treatment with
  Nivolumab (PD-1 antagnoist)
  Ipilimumab (CTLA-4 antagonist)
  29.11.18, 20.12.18, 10.01.19
- After 3rd dose: **ALT 2’800 U/L**

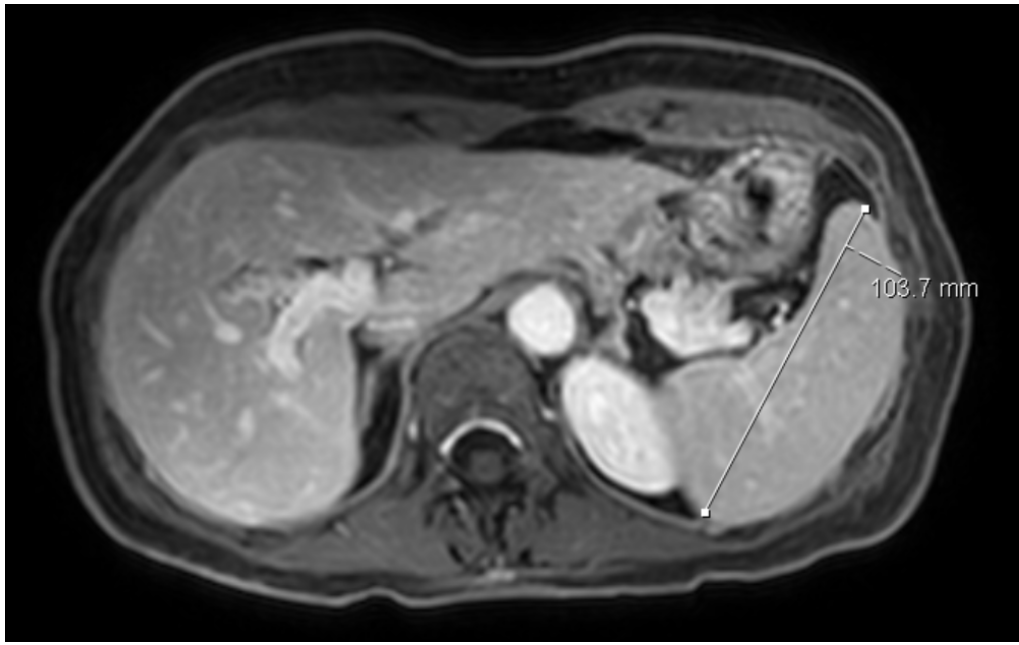

60 y/o female patient

- 17.1.2019 125 mg Methylprednisolone i.v.
- 18.1.-20.1.2019 75 mg Prednisone p.o.
- 21.1.-24-1.2019 50 mg Prednisone p.o.
- 25.1.-28.1.2019 40 mg Prednisone p.o.
- 29.1.-30.1.2019 20 mg Prednisone p.o.
- 31.1.-3.2.2019 75 mg Prednisone p.o.
- 4.2.-8.2.2019 250 mg Methylprednisolone i.v.
- 9.2.-10.2.2019 120 mg Prednisone p.o.
- 11.2.-12.2.2019 250 mg Methylprednisolone i.v.

60 y/o female patient

Exclusion of alternative aetiologies

Viral: Hepatitis A/B/C negative, CMV, EBV no acute infection

Autoimmune: ANA borderline elevated, otherwise normal

60 y/o female patient

Clinical problems

Steroid-induced diabetes mellitus

Secondary or tertiary hypothyreosis

How to proceed?

60 y/o female patient

- Switch immunosuppression to azathioprine and lower steroid dose

60 y/o female patient

- Switch immunosuppression to azathioprine and lower steroid dose
- Increase of bilirubin and all other liver tests under AZA (Bili 107 -> 265 mcmol/L)

		Anforderungsdatum	11.03.2019 13:59	04.03.2019 12:57	25.02.2019 14:29	18.02.2019 13:47	13.02.2019 14:24
		Info					
Name	Einheit	Referenz		Wert			
▼ Blut: Metabolite							
Bilirubin gesamt	µmol/L	< 17		265 +	192 +	128 +	107 +
Bilirubin direkt	µmol/L	< 5		236 +	165 +	114 +	98 +
▼ Blut: Enzyme							
ASAT	U/L	< 35		263 +	103 +	238 +	220 +
ALAT	U/L	< 35		644 +	442 +	911 +	1164 ++
alk. Phosphatase	U/L	35 - 104		219 +	144 +	165 +	147 +
G-Glutamyltransferase	U/L	< 40		760 +	748 +	777 +	583 +

60 y/o female patient

- Switch immunosuppression to azathioprine and lower steroid dose
- Increase of bilirubin and all other liver tests under AZA (Bili 107 -> 265 mcmol/L)
- AZA stop, start treatment with MMF (CellCept) 05.03.2019 (Bili 265 -> 122 mcmol/L)

		Anforderungsdatum	11.03.2019 13:59	04.03.2019 12:57	25.02.2019 14:29	18.02.2019 13:47	13.02.2019 14:24
		Info					
Name	**Einheit**	**Referenz**	**Wert**				
▼ Blut: Metabolite							
Bilirubin gesamt	µmol/L	< 17	122 +	265 +	192 +	128 +	107 +
Bilirubin direkt	µmol/L	< 5	117 +	236 +	165 +	114 +	98 +
▼ Blut: Enzyme							
ASAT	U/L	< 35	62 +	263 +	103 +	238 +	220 +
ALAT	U/L	< 35	194 +	644 +	442 +	911 +	1164 ++
alk. Phosphatase	U/L	35 - 104	235 +	219 +	144 +	165 +	147 +
G-Glutamyltransferase	U/L	< 40	1199 ++	760 +	748 +	777 +	583 +

60 y/o female patient

- Switch immunosuppression to azathioprine and lower steroid dose
- Increase of bilirubin and all other liver tests under AZA (Bili 107 -> 265 mcmol/L)
- AZA stop, start treatment with MMF (CellCept) 05.03.2019 (Bili 265 -> 122 mcmol/L)

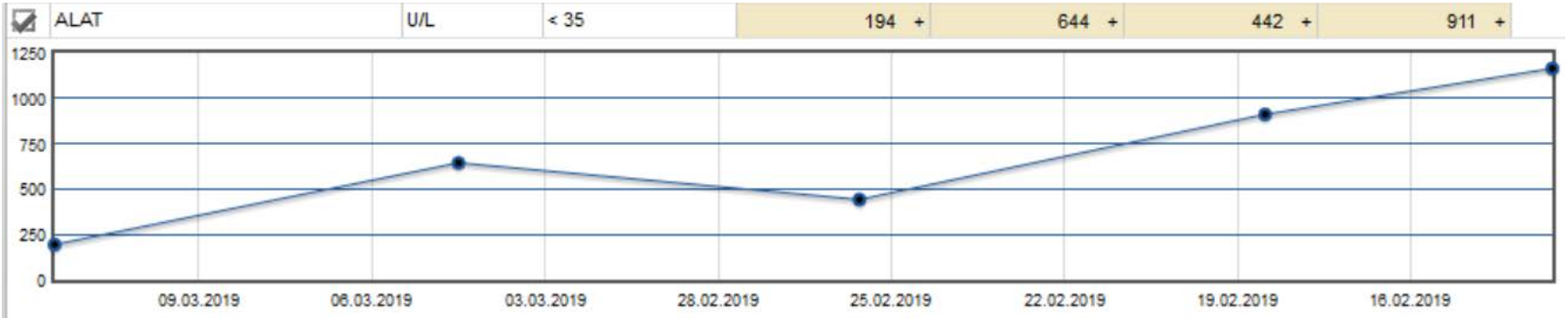

Azathioprine

- Can cause an acute, clinically apparent liver injury that is typically cholestatic.
- This complication is **uncommon but not rare**, occurring in approximately one in a thousand treated patients.
- The acute cholestatic injury due to azathioprine usually presents with fatigue and jaundice **after 2 to 12 months of starting therapy**.



"A stubborn misconception regarding susceptibility to hepatic injury has been the view that patients with preexisting liver disease are more likely than others to experience hepatic injury on exposure to drug that cause liver damage. There has been virtually no evidence for this view other than the observations that the adverse effects of C17-alkalyted steroids seems to be additive to preexisting impaired function and the impression that rifampin is more likely to produce hepatic injury in patients with pre-existing liver disease. Nevertheless, it seems clear that the additional drug-induced hepatic injury to chronic liver disease would be troublesome."

Hyman J. Zimmerman (1999)

N. Chalasani, Liver Meeting, San Francisco, 2018

60 y/o female patient

Clinical problems

Steroid-induced diabetes mellitus

- Start treatment with **metformin** 13.02.2019
- Switch to **insulin** 25.02.2019
- Difficult adaptation of insulin dose due to early morning low blood glucose levels

Secondary or tertiary hypothyreosis

- low TSH and low fT3/fT4
- Known complication of immunotherapy
- Improved spontaneously

Reviews in Endocrine and Metabolic Disorders (2018) 19:325–333
https://doi.org/10.1007/s11154-018-9463-2

CrossMark

Thyroid disorders induced by checkpoint inhibitors

Silvia Martina Ferrari[1] · Poupak Fallahi[2] · Fabio Galetta[1] · Emanuele Citi[1] · Salvatore Benvenga[3,4,5] · Alessandro Antonelli[1]

Checkpoint Inhibitor Associated Hepatitis

Ipilimumab
Granulomatous hepatitis and central vein endotheliitis

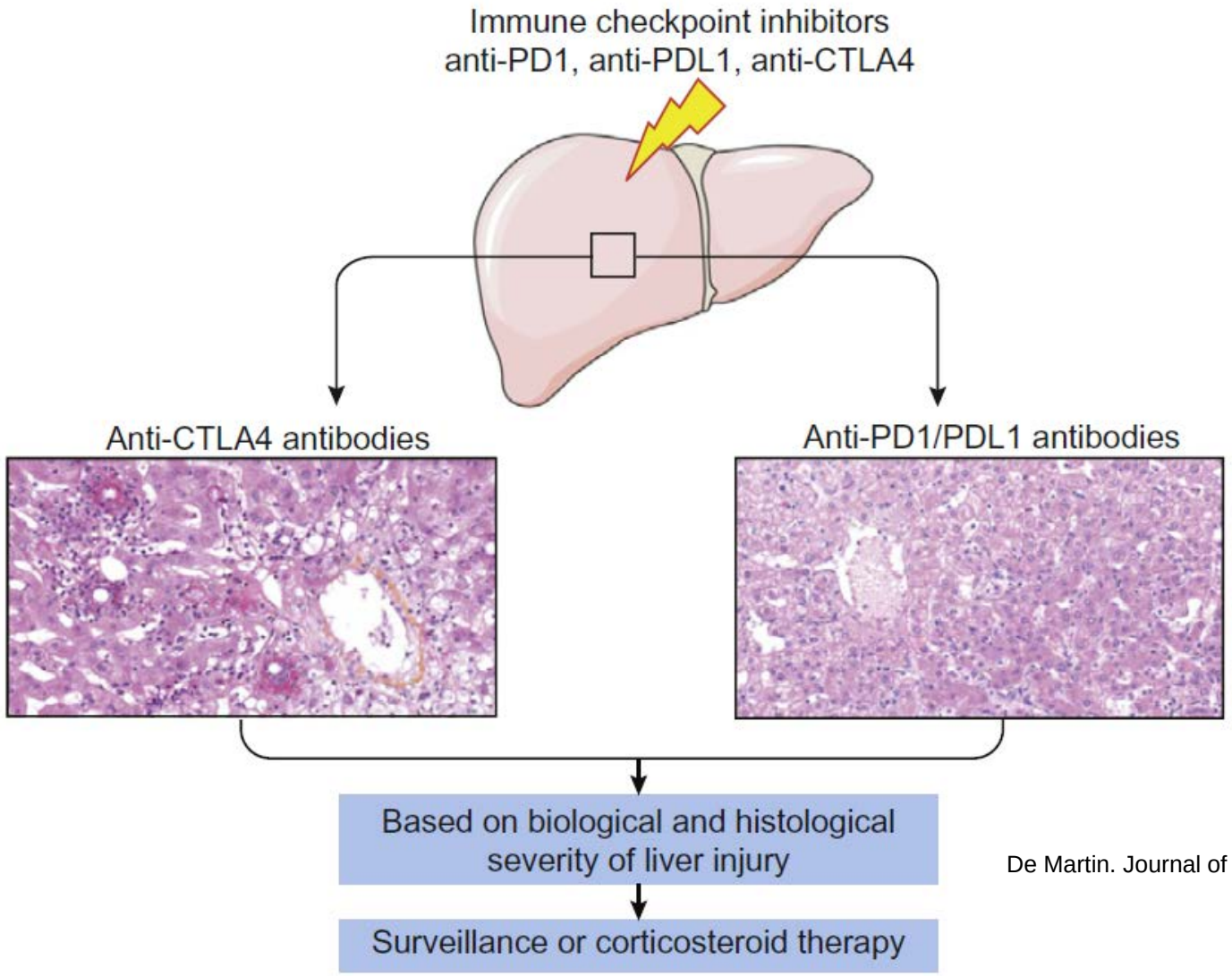

Nivolumab
Lobular hepatitis

De Martin. Journal of Hepatology 2018 vol. 68:1181–1190

12 y/o girl (*1994)

Seizuers starting in summer 2006 (at age 12)

Treatment with valproate

Fulminant liver failure 12/2006

Liver transplantation 31.12.2006

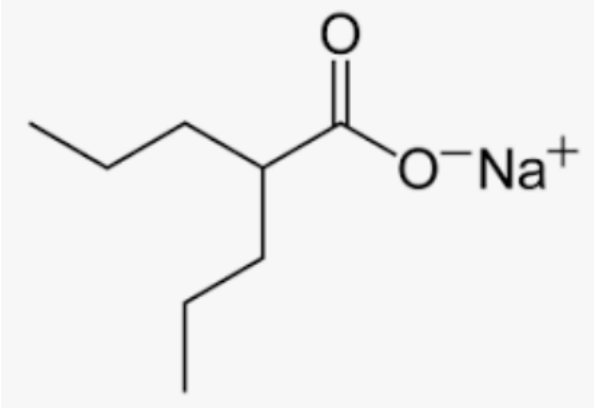

12 y/o girl (*1994)

Alpers syndrome

Hereditary mitochondriopathy

Homozygouse mutation 1399G>A in the POLG-Gen in chromosom 15 (AS A467T)

Stroke-like episode in 2007

Progressive encephalopathy

Cortical blindness

Ongoing seizures

LIVER TRANSPLANTATION 20:1402–1412, 2014

ORIGINAL ARTICLE

Acute Liver Failure After Valproate Exposure in Patients With *POLG1* Mutations and the Prognosis After Liver Transplantation

Johanna Hynynen,[1,2*] Tuomas Komulainen,[1,2*] Eija Tukiainen,[3] Arno Nordin,[3] Johanna Arola,[4] Reetta Kälviäinen,[5,6] Leena Jutila,[5] Matias Röyttä,[7] Reetta Hinttala,[1,2] Kari Majamaa,[2,8] Heikki Mäkisalo,[3] and Johanna Uusimaa[1,2]

[1]Institute of Clinical Medicine, Department of Pediatrics, University of Oulu, Oulu, Finland; [2]Medical Research Center, Oulu University Hospital, University of Oulu, Oulu, Finland; [3]Division of Transplantation and Liver Surgery, Helsinki University Central Hospital, Helsinki, Finland; [4]Department of Pathology, University of Helsinki, Helsinki, Finland; [5]Department of Neurology, Kuopio University Hospital, Kuopio, Finland; [6]Institute of Clinical Medicine, School of Medicine, Faculty of Health Sciences, University of Eastern Finland, Kuopio, Finland; [7]Department of Pathology, Turku University Hospital, University of Turku, Turku, Finland; and [8]Institute of Clinical Medicine, Department of Neurology, University of Oulu, Oulu, Finland

Our predictors may be good at predicting the ordinary, but not the irregular, and this is where they ultimately fail.

Nassim Nicholas Taleb, The Black Swan

www.swissliver.ch

INSELSPITAL
UNIVERSITÄTSSPITAL BERN
HOPITAL UNIVERSITAIRE DE BERNE
BERN UNIVERSITY HOSPITAL

UNIVERSITÄT BERN